

# Extracorporeal shock wave treatment for chronic calcific rotator cuff tendonitis



C P Roberts FRCS (Tr. and Orth.), K Cutbush FRACS, J MacCarthy DCRR, Lithotripter, D Gilpin FRACS, P F R Duke FRACS, M Ross FRACS

From the Brisbane Hand & Upper Limb Clinic, Arnold Janssen Centre, Brisbane Private Hospital, 259 Wickham Terrace, Brisbane, Qld 4000, Australia.

## BACKGROUND

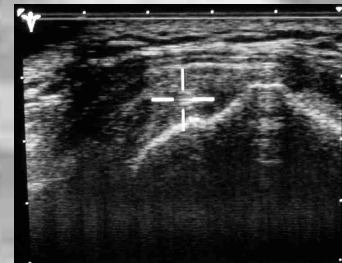
Surgery is commonly recommended for chronic painful calcific tendonitis of the shoulder unresponsive to standard non-operative treatments. We report on the use of extracorporeal shock wave treatment as an alternative to surgery.

## METHODS

Prospectively collected visual analogue pain scores of a consecutive series of 25 patients (26 shoulders) undergoing extracorporeal shock wave treatment for chronic calcific tendonitis of the shoulder were collected. Patients were later reviewed by follow-up questionnaire. Patients were enrolled between January 2001 and August 2002. Patients were followed for a minimum of 6 months post treatment. There was no loss to follow up. Treatment was carried out using a Dornier EPOS Ultra lithotripsy machine by a single operator. The shockwave was formed as a cigar shaped focus. Treatment was started at the lowest energy for every treatment and progressively increased from 0.03mJ per shock at level 1 to 0.5mJ per shock at level 9 depending on patient tolerance. The shock rate was also changed from 60-240 shocks per second again depending on patient tolerance.

## RESULTS

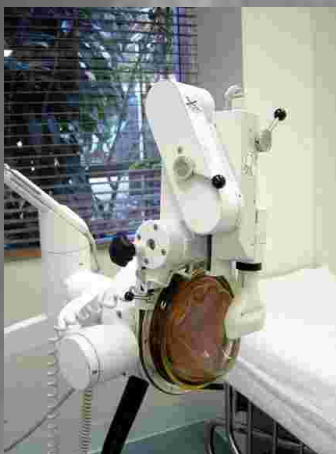The average length of follow up was 18 months (range 7-26 months). The average age of the patients was 49 years (range 28-65 years). Nine patients were male and 16 female. Visual analogue pain scores showed a symptomatic improvement by 6 weeks with further improvement by 3 months. This improvement was maintained in the longer term. Only 4 patients had to undergo surgery for recalcitrant pain. No complications of the treatment were observed.



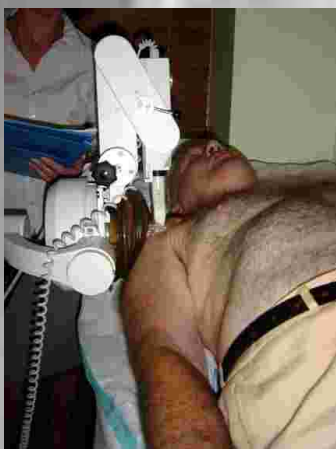USS Focus for Lithotripsy

Table 1

Visual Analogue Pain Scores				
	Mean	S.D.	Variance	Patients
Initial	5.8	2.0	3.9	26
Six weeks	3.0	2.3	5.1	26
Three months	1.7	1.5	2.3	25
Questionnaire	1.9	2.4	5.8	19

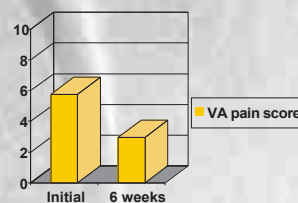


Lithotripter

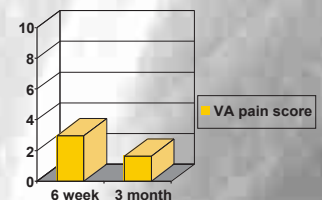


Lithotripter & patient

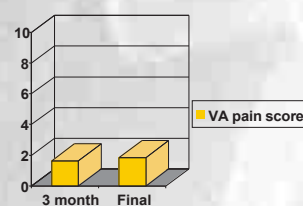
INITIAL VS 6 WEEK PAIN SCORES



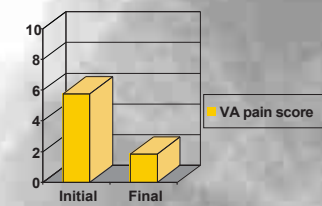
6 WEEK VS 3 MONTH PAIN SCORES



3 MONTH VS FINAL PAIN SCORES



INITIAL VS FINAL PAIN SCORES



## CONCLUSIONS

Extracorporeal shock wave treatment is a safe and successful alternative to surgery in the treatment of chronic painful calcific tendonitis of the shoulder.

## REFERENCES

- Haake M, Deike B, Thon A, Schmitt J. Exact focusing of extracorporeal shock wave therapy for calcifying tendinopathy. *Clin Orth* 2002; 397: 323-331.
- Uthoff HK, Sarkar K, Maynard JA. Calcifying tendonitis: a new concept of its pathogenesis. *Clin Orth* 1976; 118: 164-168.
- Rompe JD, Zoellner J, Nafe B. Shock wave therapy versus conventional surgery in the treatment of calcifying tendonitis of the shoulder. *Clin Orth* 2001; 387: 72-82.
- Rompe JD, Rumler F, Hopf C, Nafe B, Heine J. Extracorporeal shock wave therapy for calcifying tendonitis of the shoulder. *Clin Orth* 1995; 321: 196-201.
- Ogden JA, Toth-Kischkat A, Schultheiss R. Principles of shock wave therapy. *Clin Orth* 2001; 387: 8-17.