

Idiopathic scoliosis and pineal lesions in Australian children

GA Day, IB McPhee, J Tuffley, F Tomlinson

University of Queensland, Australia

R Chaseling, S Kellie

The Children's Hospital at Westmead, Australia

I Torode, M Sherwood

Royal Children's Hospital Victoria, Australia

K Cutbush

Mater Children's Hospital, Australia

AJ Geddes, B Brankoff

Princess Margaret Hospital for Children, Perth, Australia

ABSTRACT

Purpose. To determine whether treatment of pineal lesions in children is associated with development of idiopathic scoliosis.

Methods. 38 boys and 10 girls with pineal lesions were identified. Their mean age at presentation was 10 years. The pineal pathology varied from cysts and epidermoid to teratoma, germinoma, pineocytoma, and glioblastoma. Treatment ranged from biopsy/extirpation to radiotherapy.

Results. 12 patients died. No scoliosis was found in any females or any of the deceased. Two boys had scoliosis: one had a 12-degree right upper thoracic curve with 32-degree kyphosis and the other had a 60-degree right thoracolumbar idiopathic curve, requiring a 2-stage arthrodesis.

Conclusion. Pineal ablation is not related to the development of idiopathic scoliosis in humans.

Key words: pineal gland; scoliosis

INTRODUCTION

The relationship between pinealectomy, melatonin levels, and development of scoliosis is controversial and the results from animal studies are contradictory. Experimental pinealectomy in 3-day-old white leghorn chickens of both sexes leads to the development of thoracic scoliosis,^{1,2} whereas a sham procedure does not.^{3,4} The critical step is to remove the entire pineal gland and/or stalk.^{5,6} 50 to 100% of pinealectomised chickens develop scoliosis.^{1,3,7-10} Although the incidence of scoliosis is dependent on age at pinealectomy,¹¹ the prevalence of scoliosis in chickens pinealectomised between 2 and 18 days after hatching is not significantly different.⁴ The induced scoliosis was similar to human idiopathic scoliosis.² Angular thoracic scoliosis has been reported in some pinealectomised chickens as well as controls.^{10,12} Intra-muscular auto-transplantation of the pineal gland into pinealectomised chickens prevented the scoliosis developing in 90% of them,² but this was subsequently refuted.^{13,14}

Melatonin (N-acetyl-5-methoxytryptamine) is the only hormone secreted by the poultry pineal gland.¹⁵

Table
Patient characteristics and outcomes

Patient No.	Sex/age (years)	Diagnosis	Surgery	Radiotherapy	Chemo-therapy	Died	Lesion site	Scoliosis
1	M/11	Central nervous system germinoma	Yes	Yes	Yes	No	Pineal	No
2	M/12	Intracranial germ cell	Yes	No	Yes	No	Pineal	No
3	F/9	Intracranial germ cell	No	Yes	No	Yes	Pineal	No
4	M/14	Intracranial germ cell	Yes	Yes	Yes	No	Pineal	No
5	M/4	Intracranial germ cell	No	No	Yes	No	Pineal	No
6	M/16	Intracranial germ cell	Yes	Yes	Yes	No	Pineal & suprasellar	No
7	M/13	Intracranial germ cell	Yes	No	Yes	No	Pineal & suprasellar	No
8	M/15	Intracranial germ cell	Yes	Yes	No	No	Pineal	No
9	F/13	Intracranial germ cell	Yes	No	Yes	Yes	Pineal	No
10	M/9	Intracranial germ cell	Yes	Yes	Yes	No	Pineal & suprasellar	No
11	M/11	Intracranial germ cell	Yes	No	Yes	No	Pineal	No
12	M/14	Intracranial germ cell	Yes	No	Yes	No	Pineal	No
13	M/15	Intracranial germ cell	Yes	No	Yes	No	Pineal	No
14	M/13	Intracranial germ cell	Yes	Yes	Yes	Yes	Pineal	No
15	M/9	Intracranial germ cell	Yes	Yes	Yes	Yes	Pineal	No
16	M/14	Intracranial germ cell	Yes	Yes	No	No	Pineal & suprasellar	No
17	M/14	Intracranial germ cell	Yes	Yes	Yes	No	Pineal	No
18	F/2	Intracranial germ cell	No	No	No	Yes	Pineal	No
19	M/8	Intracranial germ cell	Yes	Yes	Yes	No	Pineal	No
20	M/9	Intracranial germ cell	No	Yes	Yes	No	Pineal	No
21	M/13	Intracranial germ cell	Yes	Yes	Yes	No	Pineal	No
22	M/10	Intracranial germ cell	Yes	Yes	Yes	No	Pineal	No
23	F/3	Pinealoblastoma	Yes	Yes	Yes	Yes	Pineal	No
24	M/14	Pinealoblastoma	Yes	Yes	Yes	No	Pineal	No
25	M/3	Pinealoblastoma	Yes	No	Yes	Yes	Pineal	No
26	M/5	Pinealoblastoma	Yes	Yes	Yes	No	Pineal	No
27	M/11	Pineal germinoma	Yes	No	No	No	Pineal	No
28	M/5	Germ cell tumour	Yes	No	Yes	No	Pineal	T5–T8, right, 12°
29	M/12	Pineal cyst	Yes	No	No	No	Pineal	T6–L1, right, 60°
30	F/14	Calcified pineal tumour	Yes	No	No	No	Pineal	No
31	M/18	Pinealoma	No	No	No	No	Pineal	No
32	M/4	Leptomeningeal dis	Yes	Yes	No	No	Pineal	No
33	M/6	Pinealoma	No	No	No	No	Pineal	No
34	M/9	Pineal teratoma	No	No	No	Yes	Pineal	No
35	F/17	Pineoblastoma	Yes	No	No	Yes	Pineal	No
36	F/11	Pineal region astrocytoma	Yes	No	Yes	No	Pineal	No
37	M/5	Pineal glioblastoma	Yes	No	Yes	Yes	Pineal	No
38	M/13	Pinealoma	Yes	Yes	Yes	Yes	Pineal	No
39	M/5	Pineal teratoma malignant	Yes	Yes	Yes	No	Pineal	No
40	M/1	Glioma pineal region	Yes	No	No	Yes	Pineal	No
41	M/12	Pineal germ cell malignant	Yes	No	Yes	No	Pineal	No
42	M/5	Pineal-hypothalamic germ cell tumour	Yes	Yes	Yes	No	Pineal	No
43	F/12	Pineal germinoma	Yes	Yes	Yes	No	Pineal	No
44	F/5	Pineocytoma	Yes	No	No	No	Pineal	No
45	F/13	Pineal region epidermoid	Yes	No	No	No	Pineal	No
46	M/12	Pineal region teratoma	Yes	No	No	No	Pineal	No
47	M/6	Pineal germinoma	No	No	No	No	Pineal	No
48	M/12	Pineal germinoma	No	No	No	No	Pineal	No

Pinelectomy on 3-day-old chickens was associated with reduced melatonin levels and elimination of the melatonin circadian rhythm.¹⁶ Although a low serum melatonin level was reportedly associated with scoliosis in pinealectomised chickens,¹⁶ others

found it a poor indicator for scoliosis.^{4,17} Induced melatonin suppression by constant light resulted in scoliosis in 15% of white leghorn chickens,¹⁸ but it had no effect on Nihon chickens.⁹ Intra-peritoneal injections of melatonin (2.5 mg/100 mg body weight)

into pinealectomised white leghorn chickens for 3 weeks prevented scoliosis in 80%,¹⁶ but injections of melatonin (2.5 mg/1 kg body weight) had no effect on pinealectomised Mountain Hubbard chickens.¹⁹ The latter dose was to restore melatonin levels to a physiological range. Daily intraperitoneal injections of 5-hydroxy-L-tryptophan (a precursor of both serotonin and melatonin) into white leghorn pinealectomised chickens retarded scoliosis development in 30% of all the chickens.²⁰

Other animal pinealectomy models (e.g. hamsters) also result in scoliosis.⁸ Scoliosis did not develop in pinealectomised quadrupedal rats but developed in all pinealectomised bipedal male Sprague-Dawley rats suggesting a postural mechanism.²¹ Scoliosis did not develop in young pinealectomised rhesus monkeys after a mean follow-up of 28 (range, 10–41) months.²²

Pineal tumours and related conditions in humans are rare.^{23–26} Scoliosis following pineal ablation in children has not been reported.²⁷ A retrospective study of scoliosis in children with a variety of pineal lesions may be the closest human model to compare with experimental pinealectomy in animals. We aimed to determine if idiopathic scoliosis was associated with prior treatment for pineal lesions in children.

MATERIALS AND METHODS

Medical records of 48 Australian children (38 boys and 10 girls) aged one to 18 (mean, 10) years presenting with pineal lesions between 1990 and 2003 were retrospectively studied (Table). Ethics approval was granted from relevant committees of the hospitals. Inclusion criteria were: patients with any kind of pineal lesions and non-pineal tumours compressing the pineal gland. Exclusion criteria were: patients aged >18 years at diagnosis and lesions not directly involving the pineal gland. Lesions varied from germ cell tumour, germinoma, pineoblastoma, pinealoma and teratoma to a pineal cyst and an epidermoid cyst. Melatonin levels were not recorded.

Of 36 surviving patients, clinical examination was not performed for 18 who had recently taken chest radiographs or spine magnetic resonance images (MRIs); 18 others took the Adam's forward bend test. Spine radiographs were not taken for patients with a straight spine and no truncal rotation. Thoracic and lumbar spine rotation was measured using a scoliometer. Plain chest radiographs or spine MRIs were available for the 12 deceased patients (7 boys, 5 girls) shortly before their deaths.

RESULTS

The mean follow-up period was 80 (range, 7–150) months for surviving patients and 30 (range, 1–142) months for the deceased. 39 patients underwent pineal gland surgery (partial or total excisional biopsy). 22 and 30 patients underwent adjuvant radiotherapy and chemotherapy, respectively.

None of the deceased were noted to have idiopathic scoliosis on their final chest radiographs or spine MRIs. Among the 36 survivors, only 2 of the 31 boys were noted to have scoliosis. One with a germ cell tumour at the age of 5 years had a 12° upper right thoracic scoliosis and a 32° kyphosis 8 years later (Fig. 1). At the age of 14 years, the kyphosis did not progress, the scoliosis diminished, and the spine became nearly straight. The other presented at age 16 years with a 60° right thoracolumbar curve (Fig. 2) and underwent an excision of a pineal cyst. Four years later, he underwent a 2-stage anterior and posterior arthrodesis. One boy without scoliosis was noted to have precocious puberty.

DISCUSSION

Cross-sectional comparisons between animal and human studies may not be appropriate, particularly in regard to the relationship between pineal function, melatonin, and scoliosis. Pinealectomy-induced scoliosis in chickens has similarities to human idiopathic scoliosis. Chicken scoliosis is 3-dimensional and involves rotation of the thoracic spine, producing a rib hump.²⁸ Single and double curves occur in both chicken and human scoliosis. The vertebral bodies in chicken and human idiopathic thoracic scoliosis are laterally wedged at the apex of the curve.^{10,29,30} The vertebral wedging may be due to anatomic changes in the vertebral growth plates.¹ Differential pressures on the quadrants of the vertebral growth plates can cause the anatomic changes.^{31,32} Anatomic differences between human and chicken spines cloud the comparisons of scolioses.^{3,28} With spinal growth, most lumbar and thoracic vertebrae of chickens fuse,²⁸ whilst human vertebrae do not fuse spontaneously. In chickens the thoracic spine is naturally lordotic, whilst in humans it is kyphotic. A relative overgrowth of the anterior elements of the human spine, resulting in thoracic lordosis, is important in the pathogenesis of the 3-dimensional deformity of thoracic scoliosis.³³ This theory has been supported by radiological and MRI studies of idiopathic scoliosis.^{34,35} Chicken scoliosis has no predilection for gender or side, whereas human idiopathic scoliosis commonly occurs

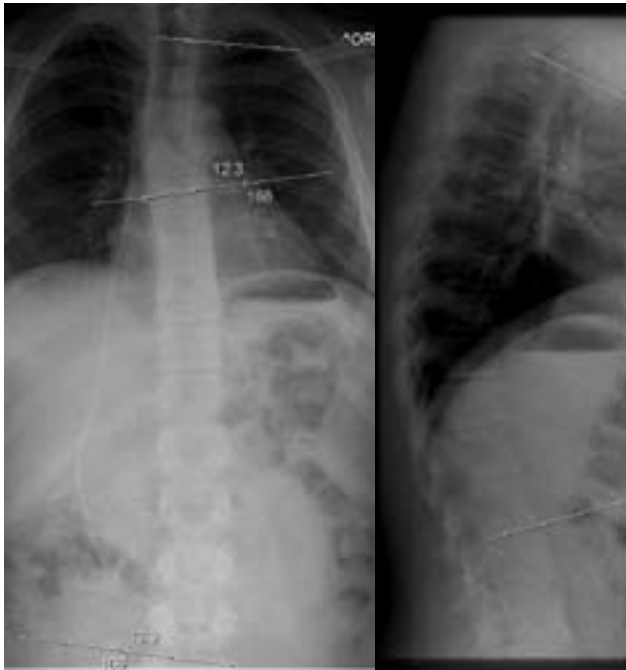

Figure 1 Radiographs of a 13-year-old boy showing a 12° upper right thoracic scoliosis and a 32° kyphosis.

on the right side of female thoracic spines. Scoliosis in pinealectomised chickens is only in the thoracic spine,⁸ whereas human idiopathic scoliosis can also occur in the lumbar spine. The thoracolumbar junction was identified as the apex of the scoliotic curve in pinealectomised chickens.³⁶

Although pinealectomy causes scoliosis in 50 to 100% of chickens, scoliosis also develops in 55 to

90% of highly inbred chickens originating from white leghorns.³⁷⁻³⁹ 68% of the inbred roosters and 46% of the hens have scoliosis.⁴⁰ Three genes are responsible for such scoliosis.⁴¹ Scoliosis has been experimentally enhanced in genetically engineered chickens by dietary means, including feeding aminonitriles or deprivation of trace nutrients such as copper, Vitamin B-6, or manganese.^{42,43} Genetic studies of adolescent idiopathic scoliosis indicate that about 11% of first-degree relatives are affected, 2.4% for second-degree relatives, and 1.4% for third-degree relatives.⁴⁴⁻⁴⁶ Monozygotic twins have a high concordance rate for idiopathic scoliosis (about 73%) compared to dizygotic twins.⁴⁷⁻⁴⁹ Genetic linkages to chromosomes 6p, 10q, 18q,⁵⁰ 19p13,⁵¹ 17p11,⁵² and X⁵³ for adolescent idiopathic scoliosis have been reported.

The relevance of melatonin secretion in chickens to the development of experimental scoliosis is conflicting. Human adolescents^{54,55} and juveniles⁵⁶ with progressive idiopathic scoliosis were reported to have reduced night-time serum levels of melatonin, although these findings have not been confirmed.⁵⁷⁻⁵⁹ Methods for identifying melatonin secretion varied between studies and included night-time and day-time serum levels as well as 24-hour urinary excretion measurements. Because the ages of scoliotic subjects varied between reports, melatonin levels could influence pre-menarchal scoliotic development rather than in adolescence.⁶⁰ An abnormality of melatonin receptors was implicated in a study on Hereditary Lordoscoliotic Rabbits.⁶¹ Polymorphism of melatonin 1A receptor on chromosome 4q was not linked with human idiopathic scoliosis.⁶² Impaired melatonin signalling was linked with human idiopathic scoliosis but melatonin receptors were normal.⁶³

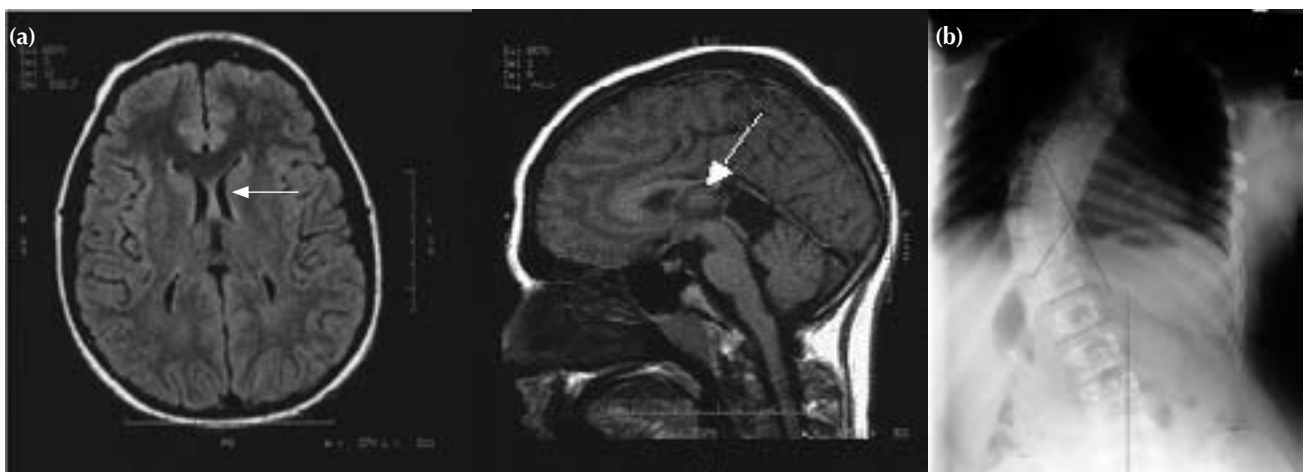


Figure 2 (a) Magnetic resonance images of the brain of a 12-year-old boy showing a pineal cyst (arrows). (b) Radiograph showing right thoracic scoliosis at the age of 16 years.

Melatonin binds to platelet calmodulin with high affinity and acts as a calmodulin antagonist.²² Platelet calmodulin is a critical mediator of cellular calcium function and a regulator of many enzymes. Elevated platelet calmodulin levels are found in children with progressive scoliosis.^{64,65} Current controversy focuses on the lack of control data and the large variability of baseline platelet calmodulin levels in idiopathic scoliosis patients.⁶⁶

For the purpose of clinical neuromotor assessment of children with idiopathic scoliosis, MRIs of the brain and spinal cord can help in the investigation of abnormalities of proprioception, postural equilibrium control, oculovestibular function, and vibratory sensation.⁶⁷⁻⁷¹ Younger children with progressive idiopathic scoliotic curves with and without neuromotor signs are more likely to have brain stem abnormalities such as Arnold-Chiari type-1 malformation, syringomyelia, or cerebellar tonsillar ectopia.⁷²⁻⁷⁷ However, lesions involving the suprasellar region and pineal gland in juveniles have not been implicated in the development of idiopathic scoliosis.

Fundamental differences exist between methodologies of experimental chicken pinealectomy and this observational human study on the effects/treatment of pineal lesions and the development of scoliosis. The chicken model was prospective and controlled with definitive proof of pinealectomy, but this study was not. The chicken pineal gland sits on the end of a long stalk in the frontal region of the brain, whereas in the human it is situated posterior to the pituitary gland. Pinealectomy was performed for chickens, whereas surgery, chemotherapy, radiotherapy, and/or ablation were performed for humans. These latter procedures may also affect the

hypothalamus and suprasellar region.

The inability to confirm the timing and complete ablation of pineal function and any corresponding reduction of melatonin levels compromised the validity of our findings. Juvenile human serum melatonin levels appear to have a large standard deviation, severely limiting the usefulness of periodically recorded melatonin levels. The lack of complete radiological studies of the entire cohort and the lack of reliability of the scoliometer to detect scoliosis were other considerations. Nonetheless, our results demonstrated a trend.

The confirmation of scoliosis ultimately depends on radiological examination. According to the Scoliosis Research Society, the phenotypic definition of scoliosis is a lateral curvature of the spine of $>10^\circ$ with rotation of the vertebrae within the curve. The validity of our study depends on the reliability, sensitivity, and specificity of the Adam's forward bending test and the scoliometer to detect a rotational asymmetry indicative of scoliosis. The scoliometer is considered adequate, reliable, and reproducible in detecting rib hump rotation.⁷⁸⁻⁸³ The correlation between asymmetry and scoliosis of $>10^\circ$ is high. In our study, patients with rib humps detected with a scoliometer had radiological studies to confirm the presence of scoliosis. It was unlikely that we missed a small scoliosis due to a false negative reading or misinterpretation of an Adam's forward bending test.

If the chicken model of experimental pinealectomy resulting in a 50 to 100% incidence of scoliosis was translated to human idiopathic scoliosis, then children with partial or complete pineal ablation should have had a substantially higher prevalence of scoliosis than 2 out of 48.

REFERENCES

1. Thillard MJ. Deformation de la colonne vertebrale consecutives a lepiphysectomie chez le poussin. Extrait des Comptes Rendus de l'Association des Anatomistes. XLVI, 1959:22-6.
2. Machida M, Dubousset J, Imamura Y, Iwaya T, Yamada T, Kimura J. An experimental study in chickens for the pathogenesis of idiopathic scoliosis. *Spine* 1993;18:1609-15.
3. Machida M, Dubousset J, Satoh T, Murai I, Wood KB, Yamada T, et al. Pathologic mechanism of experimental scoliosis in pinealectomized chickens. *Spine* 2001;26:E385-91.
4. Inoh H, Kawakami N, Matsuyama Y, Aoki T, Kanemura T, Natsume N, et al. Correlation between the age of pinealectomy and the development of scoliosis in chickens. *Spine* 2001;26:1014-21.
5. Beuerlein M, Wilson J, Moreau M, Raso VJ, Mahood J, Wang X, et al. The critical stage of pinealectomy surgery after which scoliosis is produced in young chickens. *Spine* 2001;26:237-40.
6. Beuerlein M, Wang X, Moreau M, Raso J, Mahood J, Bagnall K. Development of scoliosis following pinealectomy in young chickens is not the result of an artifact of the surgical procedure. *Microsc Res Tech* 2001;53:81-6.
7. Wang X, Jiang H, Raso J, Moreau M, Mahood J, Zhao J, et al. Characterization of the scoliosis that develops after pinealectomy in the chicken and comparison with adolescent idiopathic scoliosis in humans. *Spine* 1997;22:2626-35.
8. O'Kelly C, Wang X, Raso J, Moreau M, Mahood J, Zhao J, et al. The production of scoliosis after pinealectomy in young chickens, rats, and hamsters. *Spine* 1999;24:35-43.
9. Cheung KM, Lu DS, Poon AM, Wang T, Luk KD, Leong JC. Effect of melatonin suppression on scoliosis development in chickens by either constant light or surgical pinealectomy. *Spine* 2003;28:1941-4.

10. Coillard C, Rivard CH. Vertebral deformities and scoliosis. *Eur Spine J* 1996;5:91–100.
11. Illes T, Horvath G. Pinealectomy and scoliosis. *J Bone Joint Surg Am* 2000;82:1197–8.
12. Fagan A, Fazzalari N. Pinealectomy and scoliosis in the chicken: morphology and relationship to melatonin levels. *Proceedings Spine Society Australia*; 2004.
13. Bagnall KM, Beuerlein M, Johnson P, Wilson J, Raso VJ, Moreau M. Pineal transplantation after pinealectomy in young chickens has no effect on the development of scoliosis. *Spine* 2001;26:1022–7.
14. Turgut M, Yenisey C, Uysal A, Bozkurt M, Yurtseven ME. The effects of pineal gland transplantation on the production of spinal deformity and serum melatonin level following pinealectomy in the chicken. *Eur Spine J* 2003;12:487–94.
15. Zeman M, Buysse J, Lamosova D, Herichova I, Decuypere E. Role of melatonin in the control of growth and growth hormone secretion in poultry. *Domest Anim Endocrinol* 1999;17:199–207.
16. Machida M, Dubousset J, Imamura Y, Iwaya T, Yamada T, Kimura J. Role of melatonin deficiency in the development of scoliosis in pinealectomized chickens. *J Bone Joint Surg Br* 1995;77:134–8.
17. Wang X, Moreau M, Raso VJ, Zhao J, Jiang H, Mahood J, et al. Changes in serum melatonin levels in response to pinealectomy in the chicken and its correlation with development of scoliosis. *Spine* 1998;23:2377–82.
18. Nette F, Dolynchuk K, Wang X, Daniel A, Demianczuk C, Moreau M, et al. The effects of exposure to intense, 24 h light on the development of scoliosis in young chickens. *Stud Health Technol Inform* 2002;91:1–6.
19. Bagnall K, Raso VJ, Moreau M, Mahood J, Wang X, Zhao J. The effects of melatonin therapy on the development of scoliosis after pinealectomy in the chicken. *J Bone Joint Surg Am* 1999;81:191–9.
20. Machida M, Miyashita Y, Murai I, Dubousset J, Yamada T, Kimura J. Role of serotonin for scoliotic deformity in pinealectomized chicken. *Spine* 1997;22:1297–301.
21. Machida M, Murai I, Miyashita Y, Dubousset J, Yamada T, Kimura J. Pathogenesis of idiopathic scoliosis. Experimental study in rats. *Spine* 1999;24:1985–9.
22. Cheung KM, Wang T, Poon AM, Carl A, Tranmer B, Hu Y, et al. The effect of pinealectomy on scoliosis development in young nonhuman primates. *Spine* 2005;30:2009–13.
23. Kitay JI. Pineal lesions and precocious puberty: a review. *J Clin Endocrinol Metab* 1954;14:622–5.
24. Sklar CA, Conte FA, Kaplan SL, Grumbach MM. Human chorionic gonadotropin-secreting pineal tumor: relation to pathogenesis and sex limitation of sexual precocity. *J Clin Endocrinol Metab* 1981;53:656–60.
25. Rivarola, Belgorosky A, Mendilaharsu H, Vidal G. Precocious puberty in children with tumours of the suprasellar and pineal areas: organic central precocious puberty. *Acta Paediatr* 2001;90:751–6.
26. Nogueira K, Liberman B, Pimentel-Filho FR, Goldman J, Silva ME, Vieira JO, et al. hCG-secreting pineal teratoma causing precocious puberty: report of two patients and review of the literature. *J Pediatr Endocrinol Metab* 2002;15:1195–201.
27. Dubousset J. Scoliosis and its pathophysiology: do we understand it? *Spine* 2001;26:1001.
28. Kanemura T, Kawakami N, Deguchi M, Mimatsu K, Iwata H. Natural course of experimental scoliosis in pinealectomized chickens. *Spine* 1997;22:1563–7.
29. Stokes IA, Aronsson DD. Disc and vertebral wedging in patients with progressive scoliosis. *J Spinal Disord* 2001;14:317–22.
30. Parent S, Labelle H, Skalli W, Latimer B, de Guise J. Morphometric analysis of anatomical scoliotic specimens. *Spine* 2002;27:2305–11.
31. Mehlman CT, Araghi A, Roy DR. Hyphenated history: the Hueter-Volkman law. *Am J Orthop* 1997;26:798–800.
32. Stokes IA, Spence H, Aronsson DD, Kilmer N. Mechanical modulation of vertebral body growth. Implications for scoliosis progression. *Spine* 1996;21:1162–7.
33. Somerville EW. Rotational lordosis: the development of the single curve. *J Bone Joint Surg Br* 1952;34:421–7.
34. Dickson RA, Lawton JO, Archer IA, Butt WP. The pathogenesis of idiopathic scoliosis. Biplanar spinal asymmetry. *J Bone Joint Surg Br* 1984;66:8–15.
35. Guo X, Chau WW, Chan YL, Cheng JC. Relative anterior spinal overgrowth in adolescent idiopathic scoliosis. Results of disproportionate endochondral-membranous bone growth. *J Bone Joint Surg Br* 2003;85:1026–31.
36. Cheung KM, Wang T, Hu YG, Leong JC. Primary thoracolumbar scoliosis in pinealectomized chickens. *Spine* 2003;28:2499–504.
37. Taylor L. Inheritance of kypho-scoliosis unassociated with other defects in chickens. *Poult Sci* 1955;34:1225.
38. Taylor LW. Kyphoscoliosis in a long-term selection experiment with chickens. *Avian Dis* 1971;15:376–90.
39. Rucker R, Opsahl W, Abbott U, Greve C, Kenney C, Stern R. Scoliosis in chickens. A model for the inherited form of adolescent scoliosis. *Am J Pathol* 1986;123:585–8.
40. Riggins RS, Abbott UK, Ashmore CR, Rucker RB, McCarrey JR. Scoliosis in chickens. *J Bone Joint Surg Am* 1977;59:1020–6.
41. McCarrey JR, Abbott UK, Benson DR, Riggins RS. Genetics of scoliosis in chickens. *J Hered* 1981;72:6–10.
42. Opsahl W, Abbott U, Kenney C, Rucker R. Scoliosis in chickens: responsiveness of severity and incidence to dietary copper. *Science* 1984;225:440–2.
43. Greve C, Trachtenberg E, Opsahl W, Abbott U, Rucker R. Diet as an external factor in the expression of scoliosis in a line of susceptible chickens. *J Nutr* 1987;117:189–93.
44. Harrington PR. The etiology of idiopathic scoliosis. *Clin Orthop Relat Res* 1977;126:17–25.
45. Miller NH. Genetics of familial idiopathic scoliosis. *Clin Orthop Relat Res* 2002;401:60–4.
46. Riseborough EJ, Wynne-Davies R. A genetic survey of idiopathic scoliosis in Boston, Massachusetts. *J Bone Joint Surg Am* 1973;55:974–82.
47. Carr AJ. Adolescent idiopathic scoliosis in identical twins. *J Bone Joint Surg Br* 1990;72:1077.
48. Kesling KL, Reinker KA. Scoliosis in twins. A meta-analysis of the literature and report of six cases. *Spine* 1997;22:2009–15.
49. van Rhijn LW, Jansen EJ, Plasman CM, Veraart BE. Curve characteristics in monozygotic twins with adolescent idiopathic

- scoliosis: 3 new twin pairs and a review of the literature. *Acta Orthop Scand* 2001;72:621–5.
50. Wise CA, Barnes R, Gillum J, Herring JA, Bowcock AM, Lovett M. Localization of susceptibility to familial idiopathic scoliosis. *Spine* 2000;25:2372–80.
 51. Chan V, Fong GC, Luk KD, Yip B, Lee MK, Wong MS, et al. A genetic locus for adolescent idiopathic scoliosis linked to chromosome 19p13.3. *Am J Hum Genet* 2002;71:401–6.
 52. Salehi LB, Mangino M, De Serio S, De Cicco D, Capon F, Semprini S, et al. Assignment of a locus for autosomal dominant idiopathic scoliosis (IS) to human chromosome 17p11. *Hum Genet* 2002;111:401–4.
 53. Justice CM, Miller NH, Marosy B, Zhang J, Wilson AF. Familial idiopathic scoliosis: evidence of an X-linked susceptibility locus. *Spine* 2003;28:589–94.
 54. Machida M, Dubousset J, Imamura Y, Miyashita Y, Yamada T, Kimura J. Melatonin. A possible role in pathogenesis of adolescent idiopathic scoliosis. *Spine* 1996;21:1147–52.
 55. Sadat-Ali M, al-Habdan I, al-Othman A. Adolescent idiopathic scoliosis. Is low melatonin a cause? *Joint Bone Spine* 2000;67:62–4.
 56. Bagnall KM, Raso VJ, Hill DL, Moreau M, Mahood JK, Jiang H, et al. Melatonin levels in idiopathic scoliosis. Diurnal and nocturnal serum melatonin levels in girls with adolescent idiopathic scoliosis. *Spine* 1996;21:1974–8.
 57. Hilibrand AS, Blakemore LC, Loder RT, Greenfield ML, Farley FA, Hensinger RN, et al. The role of melatonin in the pathogenesis of adolescent idiopathic scoliosis. *Spine* 1996;21:1140–6.
 58. Fagan AB, Kennaway DJ, Sutherland AD. Total 24-hour melatonin secretion in adolescent idiopathic scoliosis. A case-control study. *Spine* 1998;23:41–6.
 59. Brodner W, Krepler P, Nicolakis M, Langer M, Kaider A, Lack W, Waldhauser F. Melatonin and adolescent idiopathic scoliosis. *J Bone Joint Surg Br* 2000;82:399–403.
 60. Dubousset J. Point of view. *Spine* 1996;21:1978.
 61. Sobajima S, Kin A, Baba I, Kanbara K, Semoto Y, Abe M. Implication for melatonin and its receptor in the spinal deformities of hereditary lordoscoliotic rabbits. *Spine* 2003;28:554–8.
 62. Morcuende JA, Minhas R, Dolan L, Stevens J, Beck J, Wang K, Weinstein SL, et al. Allelic variants of human melatonin 1A receptor in patients with familial adolescent idiopathic scoliosis. *Spine* 2003;28:2025–9.
 63. Moreau A, Wang DS, Forget S, Azeddine B, Angeloni D, Fraschini F, et al. Melatonin signaling dysfunction in adolescent idiopathic scoliosis. *Spine* 2004;29:1772–81.
 64. Kindsfater K, Lowe T, Lawellin D, Weinstein D, Akmakjian J. Levels of platelet calmodulin for the prediction of progression and severity of adolescent idiopathic scoliosis. *J Bone Joint Surg Am* 1994;76:1186–92.
 65. Lowe T, Lawellin D, Smith D, Price C, Hahter T, Merola A, et al. Platelet calmodulin levels in adolescent idiopathic scoliosis: do the levels correlate with curve progression and severity? *Spine* 2002;27:768–75.
 66. Lowe TG, Burwell RG, Dangerfield PH. Platelet calmodulin levels in adolescent idiopathic scoliosis (AIS): can they predict curve progression and severity? Summary of an electronic focus group debate of the IBSE. *Eur Spine J* 2004;13:257–65.
 67. Gregoric M, Pecak F, Trontelj JV, Dimitrijevic MR. Postural control in scoliosis. A statokinesimetric study in patients with scoliosis due to neuromuscular disorders and in patients with idiopathic scoliosis. *Acta Orthop Scand* 1981;52:59–63.
 68. Keessen W, Crowe A, Hearn M. Proprioceptive accuracy in idiopathic scoliosis. *Spine* 1992;17:149–55.
 69. McInnes E, Hill DL, Raso VJ, Chetner B, Greenhill BJ, Moreau MJ. Vibratory response in adolescents who have idiopathic scoliosis. *J Bone Joint Surg Am* 1991;73:1208–12.
 70. Sahlstrand T, Petruson B. A study of labyrinthine function in patients with adolescent idiopathic scoliosis. I. An electro-nystagmographic study. *Acta Orthop Scand* 1979;50:759–69.
 71. Yamada K, Yamamoto H, Nakagawa Y, Tezuka A, Tamura T, Kawata S. Etiology of idiopathic scoliosis. *Clin Orthop Relat Res* 1984;184:50–7.
 72. Inoue M, Minami S, Nakata Y, Otsuka Y, Takaso M, Kitahara H, et al. Preoperative MRI analysis of patients with idiopathic scoliosis: a prospective study. *Spine* 2005;30:108–14.
 73. Morcuende JA, Dolan LA, Vazquez JD, Jirasirakul A, Weinstein SL. A prognostic model for the presence of neurogenic lesions in atypical idiopathic scoliosis. *Spine* 2004;29:51–8.
 74. Inoue M, Nakata Y, Minami S, Kitahara H, Otsuka Y, Isobe K, et al. Idiopathic scoliosis as a presenting sign of familial neurologic abnormalities. *Spine* 2003;28:40–5.
 75. Chartier A, Martinot A, Dhellemmes P, Vallee L, Lamblin MD, Goran C, et al. Chiari type I malformation in children: presentation in 34 cases [in French]. *Arch Pediatr* 2002;9:789–96.
 76. Cheng JC, Guo X, Sher AH, Chan YL, Metreweli C. Correlation between curve severity, somatosensory evoked potentials, and magnetic resonance imaging in adolescent idiopathic scoliosis. *Spine* 1999;24:1679–84.
 77. Emery E, Redondo A, Rey A. Syringomyelia and Arnold Chiari in scoliosis initially classified as idiopathic: experience with 25 patients. *Eur Spine J* 1997;6:158–62.
 78. Sapkas G, Papagelopoulos PJ, Kateros K, Koundis GL, Boscaiinos PJ, Koukou UI, Katonis P. Prediction of Cobb angle in idiopathic adolescent scoliosis. *Clin Orthop Relat Res* 2003;411:32–9.
 79. Korovessis PG, Stamatakis MV. Prediction of scoliotic cobb angle with the use of the scoliometer. *Spine* 1996;21:1661–6.
 80. Murrell GA, Coonrad RW, Moorman CT 3rd, Fitch RD. An assessment of the reliability of the Scoliometer. *Spine* 1993;18:709–12.
 81. Cote P, Kreitz BG, Cassidy JD, Dzus AK, Martel J. A study of the diagnostic accuracy and reliability of the Scoliometer and Adam's forward bend test. *Spine* 1998;23:796–803.
 82. Pearsall DJ, Reid JG, Hedden DM. Comparison of three noninvasive methods for measuring scoliosis. *Phys Ther* 1992;72:648–57.
 83. Huang SC. Cut-off point of the Scoliometer in school scoliosis screening. *Spine* 1997;22:1985–9.